

Peroneal Tendon Disorders

A commonly overlooked cause of lateral ankle pain is pathology of the peroneal tendons. Injuries to the peroneal tendons are often misdiagnosed as lateral ankle sprains; therefore, typically, the initial treatment regimen is incorrect. What begins as an acute process that can be treated with conservative modalities progresses to a chronic condition that is highly resistant to conservative care, making surgery oftentimes a necessity. These conditions commonly present as a chronic condition with lateral ankle pain. Disorders of the peroneal tendons can be categorized into one of four groups:

- Peroneal tendinitis, tenosynovitis
- Peroneal tendon tears or ruptures
- Peroneal subluxation and dislocation
- Painful os peroneum syndrome (POPS)

Armagon and Shereff (1) explained that these four categories are not completely distinct from one another, but rather, there is a significant amount of overlapping of symptoms and findings. It is representative of a spectrum of conditions. With the increased popularity of sports in all age groups, the advancement of diagnostic modalities, and increased awareness on the part of the physician, peroneal disorders are becoming more commonly diagnosed (2,3).

ANATOMY

The lateral compartment of the leg consists of the peroneus longus and the peroneus brevis muscles. The peroneus longus muscle origin is the lateral tibial condyle and the head of the fibula. The peroneus brevis muscle has its origin at the middle one-third of the fibula and the intermuscular septum. As the tendons course distally, they share a common synovial sheath, which begins approximately 4 cm proximal to the tip of the lateral malleolus. Upon reaching the posterior aspect of the lateral malleolus, the tendons run within a fibro-osseous tunnel known as the retromalleolar or fibular groove. At this level, the peroneus longus tendon sits posterior and lateral to the peroneus brevis tendon, which abuts up against the groove. Heckman et al (4) outlined the boundaries of the fibular groove with the lateral malleolus forming the anterior wall of the fibular groove, the superior peroneal retinaculum located posterolateral, and the posterior talofibular, the calcaneofibular, and the posterior tibiotalar ligaments forming the medial wall. The most important structure in holding the peroneal tendons in place at the level of the distal fibula is the superior peroneal retinaculum. This structure is an extension of the deep fascia and originates on the posterolateral aspect of the distal fibula and inserts as two distinct bands onto the lateral calcaneal wall and the lateral aspect of the Achilles tendon sheath. Its purpose is to prevent lateral migration, subluxation, of the peroneal tendons (4,5).

Coursing distally along the lateral wall of the calcaneus, the common tendon sheath is split into two separate sheaths, a

superior and an inferior sheath, by the peroneal tubercle. The superior sheath houses the peroneal brevis tendon, while the peroneal longus is contained within the inferior sheath. From the peroneal tubercle, the peroneus brevis continues distally to insert onto the base of the fifth metatarsal, the styloid process. Hyer et al (6) pointed out that the peroneal tubercle has a cartilaginous facet on its inferior surface and the purpose of the tubercle is to assist in gliding the peroneus longus tendon distally toward the cuboid. Once it reaches the cuboid, the peroneus longus tendon makes a sharp turn within the cuboid groove and heads medially to insert onto the plantar base of the first metatarsal and the medial cuneiform. If an os peroneum is present, it is located within the peroneus longus tendon at the level of the calcaneocuboid joint.

The peroneal muscles receive their innervations from the superficial peroneal nerve. Petersen et al performed a cadaveric study of 40 healthy peroneal tendons, 20 longus tendons, and 20 brevis tendons. These peroneal tendons were injected with an immunohistochemical stain that adheres to laminin, a glycoprotein found in the basement membrane of blood vessels. What they discovered is the peroneal tendons have three areas of avascularity, which correspond with the three areas where most tendinopathy develops. The gross blood supply comes from the posterior peroneal artery and from branches of the medial tarsal artery. These arteries penetrate the posterior aspect of the peroneal tendons. The study showed the majority of each tendon is covered by a vascular-rich peritenon and that the blood supply within each tendon runs proximal to distal following the course of the tendons. Most importantly, they determined that the three zones of avascularity, one in the peroneus brevis and two in the peroneus longus, are due to interruption of these longitudinal arteries. These areas were noted to be devoid of laminin and therefore devoid of arterial vessels (7). These three areas were also noted to correspond to the following regions where the tendons run around a bony pulley:

- In the peroneus brevis where it runs against the retromalleolar groove. The length of avascularity averaged 40 mm.
- In the peroneus longus as it bends around the lateral malleolus. This area averaged 52 mm.
- In the peroneus longus as it turns medially at the cuboid, averaging 25 mm (7)

Various anatomical anomalies as well as associated pathologies have been linked to peroneal disorders. These include a shallow retromalleolar groove, a low-lying peroneal muscle belly, the presence of a peroneus quartus muscle, an enlarged peroneal tubercle, a valgus or cavovarus hindfoot, laxity of the superior peroneal retinaculum, the presence of bone spurs at the posterolateral edge of the fibula, and lateral ankle instability. As a note of caution, Saupe et al (8), in a magnetic resonance imaging (MRI) study of 65 volunteers, revealed that any one of these anatomical variants can be found in asymptomatic ankles.

Therefore, the presence of an anatomical variant does not absolutely lead to peroneal tendon disorders.

The more narrow or shallow the retromalleolar groove, the more likely instability is present when the peroneal tendons glide along the posterior aspect of the lateral malleolus. The instability leads to an increased risk of subluxation due to the increased stress applied by the tendons on the attachment site of the superior peroneal retinaculum onto the posterolateral lip of the fibula. Studies have shown the shape of the groove can present in one of three ways: convex, flat, or concave. However, both Ferran et al (9) and Heckman et al (4) assert the shape of the groove is dictated by the fibrocartilaginous lip at the posterolateral ridge of the fibula, not by the degree of groove concavity.

Anything that adds bulk within the retromalleolar groove can cause increased pressure during ankle dorsiflexion. This additional pressure leads to stenosing of the peroneal tendons and stretching of the superior peroneal retinaculum (4,5,10). Saupe et al (8) illustrated that a low-lying peroneus brevis muscle belly is one that extends more than 15 mm below the tip of the fibula. A peroneus quartus muscle, an anomalous muscle occurring in 10% to 22% of the population, originates on the peroneus muscle belly and inserts onto the peroneal tubercle. Other muscle variants of note are the peroneal digiti quinti and the peroneo-calcaneal muscles. Because of its insertion, the peroneus quartus has been linked to hypertrophy of the peroneal tubercle.

When the peroneal tubercle is hypertrophied, determined by Saupe et al to be higher than 5 mm, the increase in mechanical irritation leads to the development of stenosis and a decrease in the gliding of the tendon within its sheath. This variant is commonly linked to tears within the peroneus longus tendon because of its position inferior to the tubercle (8). A study performed by Hyer et al (6) found that 90% of their specimens had a peroneal tubercle, of which 28% were considered enlarged. Taki et al described a case of a young boy with bilaterally enlarged peroneal tubercles. Upon successful removal, the histologic results proved to be a bilateral osteochondroma (11).

When the hindfoot has a valgus deformity, crowding of the peroneal tendons take place in the retromalleolar area and the area just distal to the fibula (12). A cavovarus hindfoot causes an increase in friction in the areas of the lateral malleolus, the peroneal tubercle, and the cuboid groove leading to

tenosynovitis (4). In patients with a neurologic deficit, peroneal weakness leads to an increase in the pulling force from the posterior tibial tendon. This sets the stage for instability of the lateral ankle (13).

Lateral ankle instability refers to the loss of proprioception and function within the lateral soft tissue structures of the ankle, that is, the lateral collateral ligaments, the superior peroneal retinaculum, and the peroneal tendons. These patients are prone to repeated inversion ankle sprains, predisposing oneself to peroneal tendon injuries. When there is failure of the lateral ankle ligaments, the peroneal tendons function to keep the ankle stabilized, placing an increase in strain on the tendons (1,13,14). One study by Squires et al (13) proved various disorders of the peroneal tendons frequently occur in cases of chronic lateral ankle instability: peroneal tenosynovitis, failure of the superior peroneal retinaculum, and tearing of the peroneal brevis tendon (Fig. 77.1). A cadaveric study by DiGiovanni et al analyzed the amount of strain placed on the superior peroneal retinaculum when failure of one or more of the lateral collateral ligaments occurred. When the anterior talofibular ligament was severed, no changes in stress were noted. A 25% increase in the amount of stress across the retinaculum was recorded when both the calcaneofibular and the anterior talofibular ligaments were severed. When all three collateral ligaments were cut, stress within the superior peroneal retinaculum increased by 64%. This proves that as the degree of instability increases, so does the amount of strain placed on the superior peroneal retinaculum (1,15).

BIOMECHANICS

The peroneus longus and brevis muscles work as strong everters of the foot and weak plantarflexors of the ankle. More specifically, Root et al illustrated the functions of the peroneus longus muscle as being (a) a stabilizer of the first ray during midstance and propulsion; (b) a weak plantarflexor of the ankle joint during propulsion; (c) a strong everter of the foot during the early phase of propulsion; and (d) a weak decelerator of ankle joint dorsiflexion during the heel lift period of the propulsive phase of gait. The functions of the peroneal brevis muscle are specifically described as (a) a strong everter of the foot during midstance and propulsion; (b) a stabilizer of the fifth metatarsal

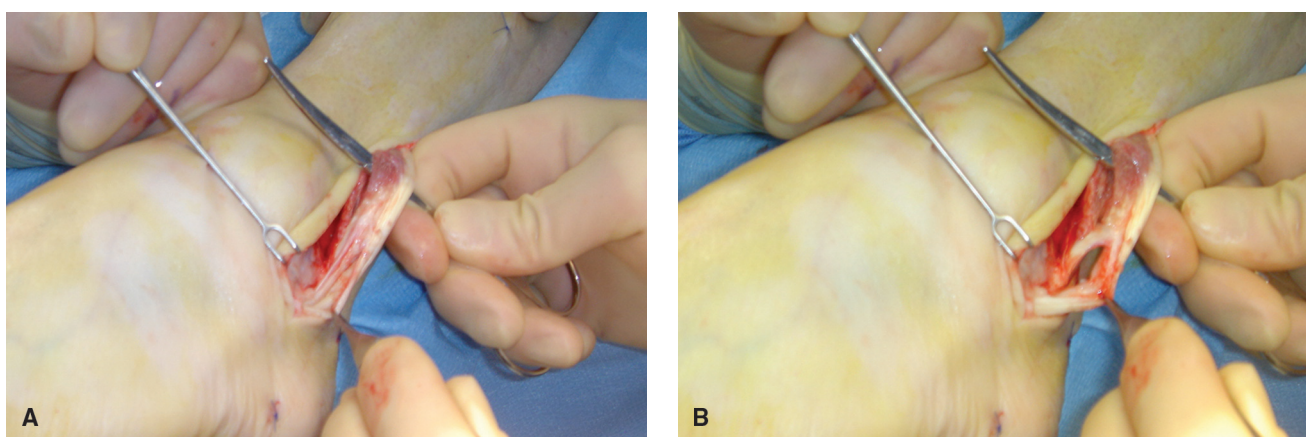


Figure 77.1 Longitudinal tears of a peroneal brevis tendon—please note the proximal and distal tears.

during midstance and early propulsion; (c) an antagonist to those muscles that supinate the subtalar and midtarsal joints; and (d) an antagonist to the lower leg muscles that supinate the foot at the subtalar joint, that is, a weak plantarflexor of the ankle (16). As antagonists to the posterior tibial, flexor hallucis longus, flexor digitorum longus, and anterior tibial muscles, both peroneal tendons function as dynamic stabilizers of the lateral collateral ankle ligaments during excessive inversion and, along with these ligaments, are important in ankle proprioception (1,4,13).

EPIDEMIOLOGY

Overall, disorders of the peroneal tendons are uncommon. They are frequently seen in those sports in which the foot and ankle perform a lot of cutting motions, snow skiing being the most common. Because they are often mistaken as lateral ankle sprains, peroneal disorders tend to go untreated. When this occurs, the delay in diagnosis and treatment leads to instability of the lateral ankle. If a patient has signs and symptoms of ankle instability, it is important to examine the peroneal tendons thoroughly because the instability may be stemming from peroneal tendinopathy. Systemic conditions have also been associated with disorders of the peroneal tendons. These include various forms of arthritis such as rheumatoid and psoriatic, tophaceous gout, hyperparathyroidism, diabetic neuropathy, the use of fluoroquinolone antibiotics, generalized ligamentous laxity, and local steroid injection (5,12,17). The buildup of gouty crystals leads to weakening of extracapsular tissue including tendons (17). Lagoutaris et al described a case in which chronic tophaceous gout infiltrated both the peroneus longus and the peroneus brevis tendons, causing a longitudinal split tear in both tendons. Chronic inflammation within the tendons can accompany the synovitis of tophaceous gout, and as the gout progresses untreated, eventual rupture of the tendons can occur (17).

Peroneal tendinitis and peroneal tenosynovitis occur secondary to repetitive or prolonged movements. To avoid confusion, inflammation located at the musculotendinous junction is termed peritendinitis, which is due to prolonged repetitive movements and presents as pain with motion of the tendon. Tenosynovitis is inflammation of the tendon sheath, which involves edema. Stenosing tenosynovitis is a result of chronic tenosynovitis and is a painful inflammatory condition in which the tendon sheath narrows and adheres to the tendon. Of all the tendons that run in the ankle region, the peroneal tendons are most commonly affected (18). Once stenosing tenosynovitis develops, there is less chance that conservative treatment will be successful. Heckman et al (4) revealed that 77% of patients with chronic lateral ankle instability have some form of peroneal tendon or peroneal tendon sheath inflammation.

Peroneal tendon tears and ruptures are most often due to an inversion ankle injury and are more common in the peroneus brevis tendon than the peroneus longus tendon (Fig. 77.2). Tears involving these tendons can also be associated with other disorders; therefore, if a tear in either peroneal tendon is diagnosed, it is important to examine for chronic tenosynovitis; fractures of the ankle, calcaneus, and talus; and chronic ankle instability (Fig. 77.3).

Although the occurrence is rare, the frequency of subluxation and dislocation of the peroneal tendons is on the rise with

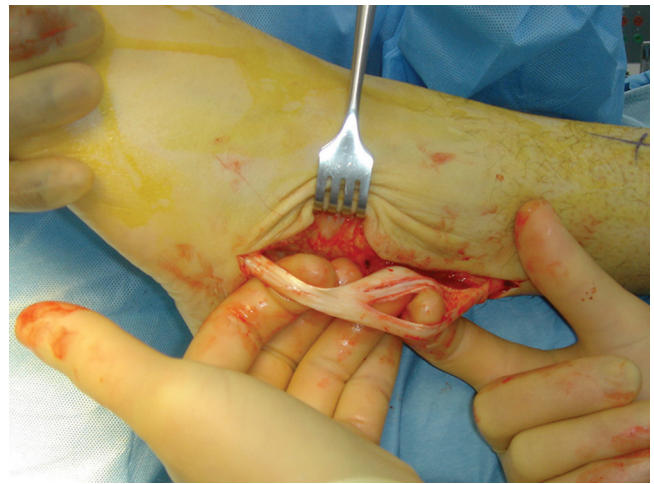


Figure 77.2 A peroneal brevis tendon with two different longitudinal tears in the retromalleolar region secondary to chronic lateral ankle instability.

the increased popularity in sports. When the ankle joint is suddenly forced into dorsiflexion, the peroneal tendons respond by undergoing severe contraction. This forced movement puts a lot of stress on the superior peroneal retinaculum to the point at which it becomes lax or ruptures. With failure of the soft

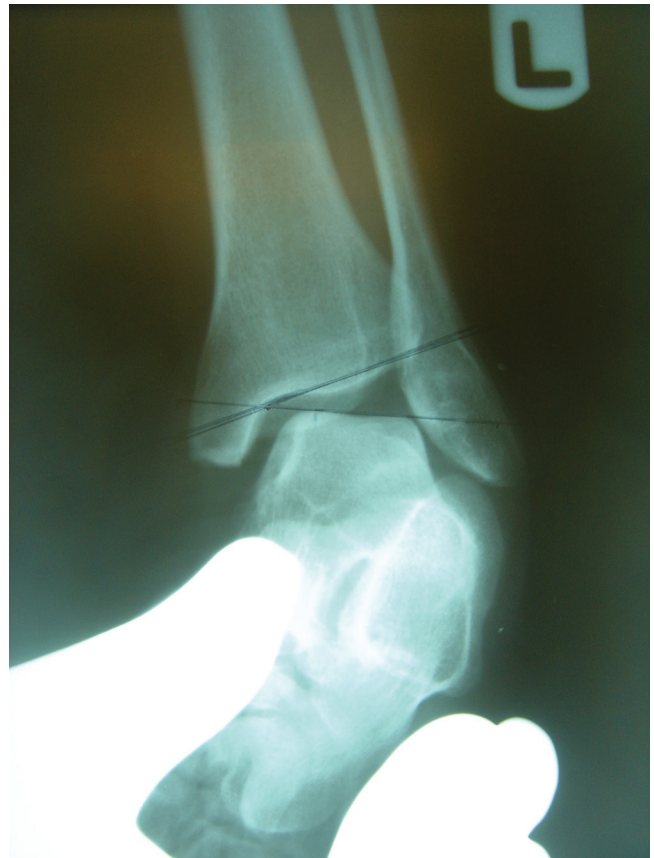

Figure 77.3 Stress radiograph demonstrating a positive talar tilt sign. This patient's condition consisted of a loss of the anterior talofibular ligament and calcaneofibular ligament as well as tearing of both peroneal brevis and peroneal longus tendons.

tissue restraint, the peroneal tendons are now able to anteriorly sublux out of the retromalleolar groove (Fig. 77.4) (10,19). This forced dorsiflexion resulting in peroneal subluxation is most commonly seen in skiing accidents but has also been tied to soccer, dancing, basketball, rugby, running, cycling, rowing, football, baseball, ice skating, gymnastics, and horseback riding (3,9,10,18–20). Peroneal subluxation has also occurred with the foot being in a plantarflexed, inverted, everted, or externally rotated position. These movements are thought to cause tightening of the calcaneofibular ligament. This tightening pushes against the superior peroneal retinaculum and brings about an increase in the amount of pressure against the retinaculum. The results are failure of the superior peroneal retinaculum and dislocation of the tendons (10,19). Trauma is the most likely cause of peroneal subluxation, occurring in 92% of the cases, while the other 8% is congenital in origin due to some type of deficit within the bone or soft tissue structures that act to prevent the peroneal tendons from subluxing (19,21). Rosenfeld et al revealed that congenital peroneal subluxation occurs in approximately 3% of newborns with over 90% resolving without any treatment necessary (19). Ogawa et al added that any congenital deformity of the bone and soft tissue of the leg can increase the risk of peroneal subluxation. These include hyperelasticity of the ligaments, congenital absence of the superior peroneal retinaculum, an anomaly of the peroneus brevis muscle, a shallow fibular groove causing bilateral congenital subluxation, congenital vertical talus, and talipes planovalgus (10). In adults, non-traumatic peroneal subluxation is most likely secondary to laxity of the superior peroneal retinaculum, a shallow fibular groove, or a distal fibula with a convex surface (19). The occurrence of peroneal subluxation along with ankle sprains is less than 0.5%. Lateral ankle instability, longitudinal split tears of the peroneus brevis tendon, attenuation of the superior peroneal retinaculum, insufficient depth of the fibular groove, and fractures of the hindfoot have also been associated with peroneal tendon subluxation. Klein et al (22) discovered that 46% of patients who suffered from a Hawkins type II lateral talar process fracture also had subluxation of the peroneal tendons.

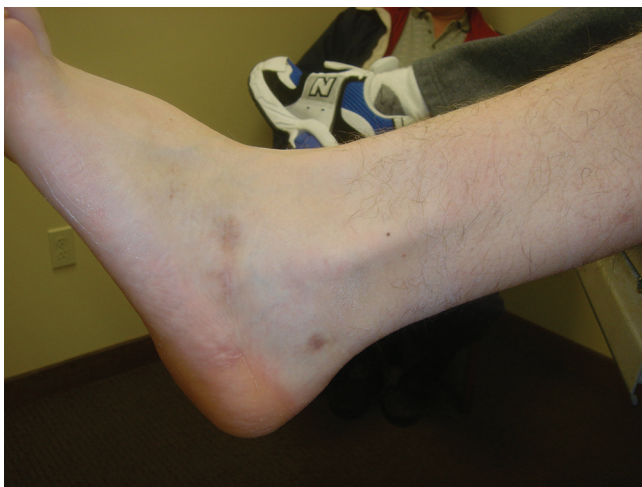

Figure 77.4 A clinical lateral view of a patient with peroneal dislocating tendon. Please note how far anterior the tendon lies and the prominence.

PHYSICAL EXAMINATION

Patients with peroneal tendon disorders relate a history of an ankle sprain that never resolved. Because they are frequently overlooked and therefore misdiagnosed, peroneal disorders are not usually picked up until several weeks to several months after the initial injury (Fig. 77.5). A study performed by DiGiovanni et al determined the type and the rate of occurrence of injuries that occur concomitantly with lateral ankle instability. Out of a total of 61 patients, 77% had peroneal tendinitis, 54% had laxity of the superior peroneal retinaculum, and 25% had a tear of the peroneus brevis tendon. The results of this study emphasize the importance of needing a high index of suspicion for associated injuries when treating chronic lateral instability of the ankle (15). This will bring about a more prompt and accurate treatment plan for the patient (4,9,13,15,18,21,23,24). As a general rule, the presence of decreased peroneal muscle strength is not a reliable finding because in many cases the strength can be normal on physical exam (4,5,20). A more reliable exam to determine the possibility of peroneal disorders is to apply stress to the lateral ankle. If there is a problem with the tendons, pain will be elicited with passive inversion of the hindfoot and plantarflexion of the ankle and with active resisted hindfoot eversion and ankle dorsiflexion. Further, Heckman et al (4) and Selmani et al (5) both suggested performing the Coleman Block test to evaluate the alignment of the hindfoot.

PERONEAL TENDINITIS AND TENOSYNOVITIS

The hallmark sign of acute peroneal inflammation is swelling with pain and warmth along the course of the tendons. These findings are not as reliable however in cases of chronic tendinitis. Even though acute trauma can cause tendinitis, the primary cause of inflammation is a repetitive motion that leads to an overuse injury (Fig. 77.6). Tendinitis can present in one of three ways: (a) acute, occurring for less than 2 weeks in which pain presents at the posterior or distal aspect of the lateral malleolus; (b) subacute, symptoms have been present between 2 and 6 weeks; and

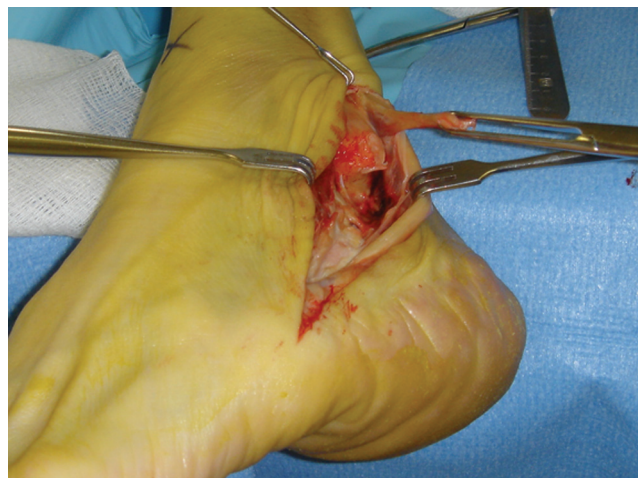


Figure 77.5 A complete tear of the peroneal brevis tendon. This patient also experienced a complete tear of the anterior talofibular ligament.

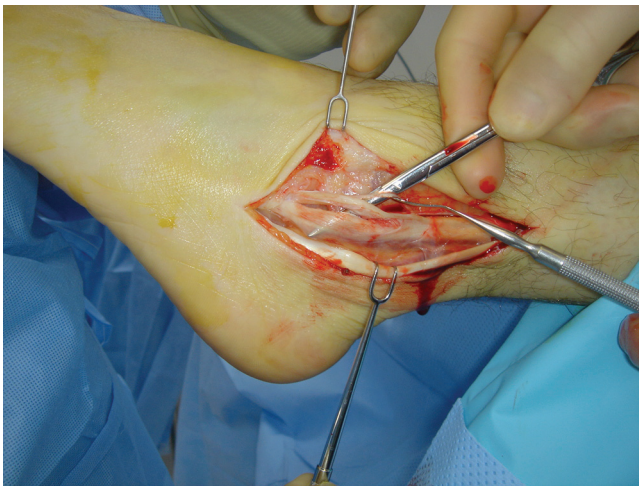

Figure 77.6 Peroneal tenosynovitis with evidence of an intrasubstance peroneus brevis tendon tear. This tear extends for approximately 1 cm. There is a longitudinal split tear of the inframalleolar portion of the peroneus brevis tendon.

(c) chronic, occurring for more than 6 weeks. The chronic situation presents as an insidious onset over weeks to months of pain at the posterolateral aspect of the ankle. To distinguish between the two tendons, peroneus brevis tendinitis can present as pain along the course of the tendon itself or at the site where it inserts onto the base of the fifth metatarsal. Pain associated with tendinitis of the peroneus longus usually presents itself over the lateral aspect of the calcaneus and distally toward the cuboid groove (4).

PERONEAL TENDON TEARS

Signs and symptoms of a peroneal tendon tear are retromalleolar pain and edema along the tendon's course. Caution must be used during the physical exam because these findings may be more pronounced in young adults and completely absent in the elderly population. Tears can be acute or chronic in nature and may or may not present with a history of ankle instability with recurrent ankle sprains (4). Muscle strength and range of motion may not be affected because if the tendon is only partially torn, the remaining portion of the tendon, if normal, can compensate; hence a false-negative finding. Specifically, the eversion muscle strength can be picked up by the extensor hallucis longus, the extensor digitorum longus, and the peroneus tertius muscles (4,5,12,13). If the physician palpates too far distal on the lateral malleolus, injuries to the calcaneofibular ligament can be mistaken for injuries to the peroneal tendons (20). Palpable localized soft tissue nodules may be present at the site of tendon disruption. This develops from degeneration that takes place within the tendon after an injury.

The most common type of tear is the longitudinal split tear that occurs within the peroneus brevis tendon as it runs in the retromalleolar groove (Fig. 77.7). A second type of tear, known as a bucket-handle tear, occurs when the peroneus longus tendon squeezes itself between the two portions of the split in the brevis tendon (13). Tearing of the peroneus brevis tendon can also occur at its insertion site on the base of the fifth metatarsal. This presentation is most often due to an inversion injury. If a patient has a history of arthritis, it is important to take note of any spur formation located at the insertion site of the superior peroneal retinaculum onto the fibula. If the retinaculum is lax, the peroneus brevis tendon runs over this area when it

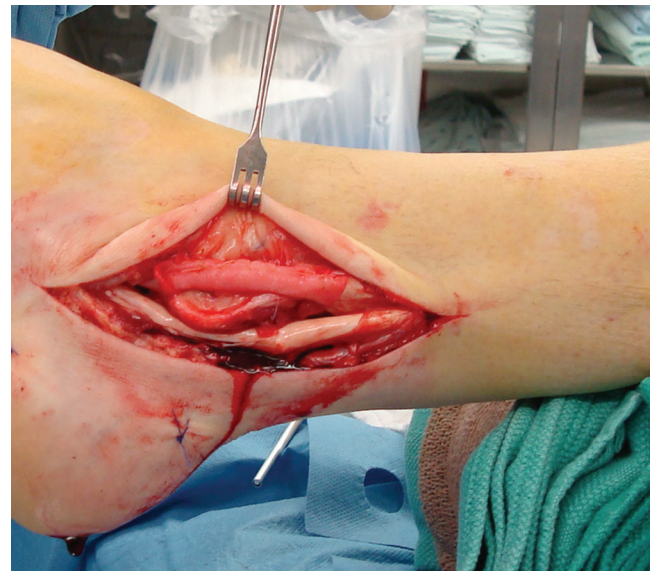

Figure 77.7 Longitudinal tearing involving the retromalleolar peroneus brevis tendon.

subluxes, eventually leading to a split tear. Stenosing tenosynovitis of the peroneus brevis is also a risk if there is any erosion of the fibrocartilage on the groove's surface.

Peroneus longus tendon tears will have pain with palpation at the cuboid or near its plantar insertion onto the base of the first metatarsal and medial cuneiform (Fig. 77.8). The latter presentation can be easily misdiagnosed as posterior tibial tendinitis because of the symptoms occurring medially. Loss or limitation of plantarflexion of the first ray points to disruption of the peroneus longus tendon. Finally, tears within the peroneus longus tendon may be associated with the presence of an os peroneum, an accessory ossicle occurring in 20% of the population (12). These patients will have pain located in the plantar lateral aspect of the foot.

Several easy examination methods can be performed when testing for a tear of the peroneal tendon. The peroneal tunnel compression test can be used in cases of suspected peroneus brevis tendon tears as well as for brevis tendinitis. This involves applying pressure to the peroneus brevis tendon in the retromalleolar groove while the knees are bent at 90 degrees and the foot is in relaxed plantarflexion. A positive exam is the presence of pain (4,5). Other methods described by Squires et al consisted of having the patient get into a runner's stretch with the affected foot posterior. A tear in the peroneal tendon will cause pain since this type of stretch passively puts the ankle into extreme dorsiflexion. The examiner can also test for tearing by having the patient perform a single-heel- or a double-heel-rise test. This specifically tests for balance and hindfoot stability and will be difficult to do in the presence of a tendon tear. Lastly, patients should be tested for the presence or absence of proprioception by having them stand on one foot with their eyes closed. The patient's inability to perform this test is a positive result (13).

PERONEAL SUBLUXATION

Subluxation of the peroneal tendons results from failure of the superior peroneal retinaculum to act as a restraint. The mechanism of injury involves a combination of an injury to the ankle

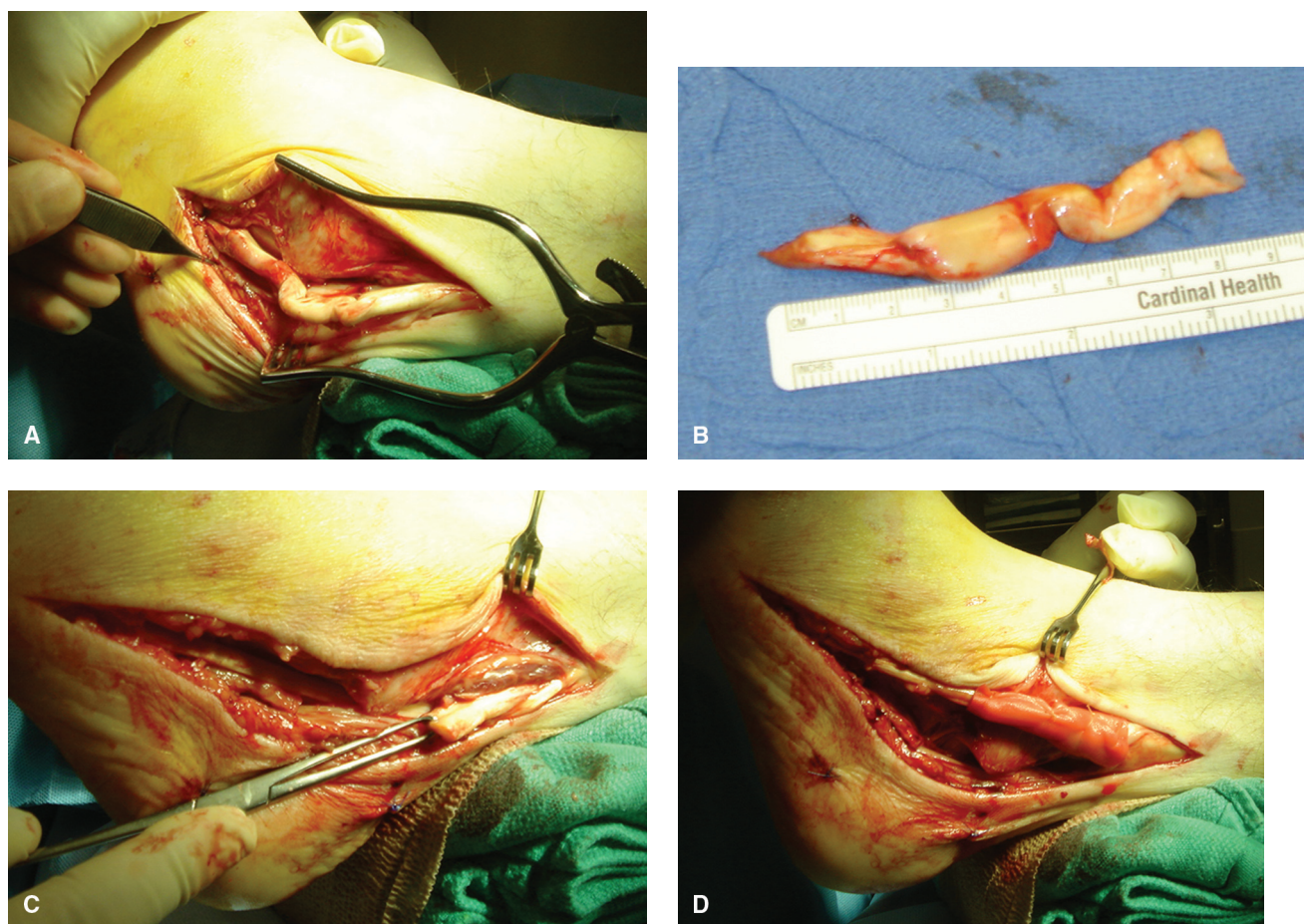


Figure 77.8 **A:** Intraoperative view of a complete tear of the peroneus longus tendon in the inframalleolar portion and in the region near the calcaneal–cuboid joint. **B:** Approximately 9 cm of retracted and corrugated peroneus longus tendon. Note the distal portion (left side of the photo) of the chronic tear. **C:** The most distal stump of the peroneus longus tendon following resection of the disease portion of the tendon. **D:** Intraoperative view of a tenodesis procedure utilizing Tissue Mend (TEI Bioscience, Boston, MA) as a graft for structural support—augmenting tendon repair.

while it is inverted and dorsiflexed and forceful contraction of the peroneal tendons. This puts an unusual amount of strain on the superior peroneal retinaculum, causing it to become stretched or torn (5). Acute cases of subluxation will present with a significant amount of swelling. Pain, tenderness, and ecchymosis will be found posterior to the lateral malleolus just proximal to the distal tip (4,12).

Chronic inversion ankle sprains leading to lateral ankle instability can bring about chronic peroneal subluxation. Further, as the tendons continue to sublux out of the retromalleolar groove, stenosing tenosynovitis of either tendon and eventual longitudinal split tears of the brevis tendon can ensue (3). Chronic peroneal subluxation is usually seen with a history of chronic ankle instability secondary to repeated inversion sprains. Peroneal disorders are too often overlooked in the face of sprains and instability; therefore, it is important to be able to differentiate between the signs and symptoms of subluxation and those of ankle sprains and instability:

- Pain associated with sprains is located at the tip of the lateral malleolus with edema at its anteroinferior aspect. In contrast, pain with subluxation is proximal to the tip of the fibular malleolus, while the edema is more posterolateral.

- During a sprain, patients recall their ankle giving way and do not trust their ankle to support them while walking on uneven surfaces. A popping or snapping sensation is felt and sometimes even heard by patients whose tendons are subluxing. Walking on uneven terrain tends not to have any effect.
- When examining the patient, certain movements will elicit pain in certain disorders. Flexion and inversion of the ankle will cause an increase in pain with sprains. Dorsiflexion and eversion of the ankle and circumduction of the foot will cause pain in cases of subluxation.
- Symptoms with lateral instability can be alleviated with a lateral heel wedge since it reduces the stress on the lateral collateral ligaments. This device will aggravate symptoms when subluxation is present.
- X-rays of sprains may show a fracture fragment at the anteroinferior aspect of the fibula on an AP view, an avulsion of the anterior talofibular ligament. Radiographs taken in cases of subluxation may show a fracture fragment at the posteroinferior fibula on an internal mortise view, a grade III retinacular injury (1,4,5).

Examination methods are available to accurately test for subluxation. A thorough exam should always include an examination

of the opposite ankle to rule out any congenital laxity of the superior peroneal retinaculum (20). Safran et al described their method of testing for peroneal tendon subluxation in which the patient lies prone on a table with the affected limb bent 90 degrees at the knee. The physician applies resistance to the foot while the patient actively moves the ankle through dorsiflexion, plantarflexion, and eversion. A positive exam is visual confirmation of the dynamic instability of the peroneal tendons (25). Another method has the patient sitting or lying supine. Manual pressure is applied to the posterior edge of the distal fibula while the patient dorsiflexes and everts the foot. This tests for pathology within the peroneus brevis tendon and, if present, will cause pain due to compression against the fibular groove (3). Finally, putting the foot through circumduction allows the peroneal tendons to sublux out of the groove. This subluxation causes the snapping, clicking, and or crepitus that can be palpated. Subluxation of the tendons can even be visualized when the patient ambulates; however, this is not very common (3,4).

PAINFUL OS PERONEUM SYNDROME

Like all peroneal tendon disorders, a high index of suspicion is needed to accurately diagnose this syndrome. Mechanisms of injury include an eversion force placed on a supinated foot, pushing off while the foot is inverted, and direct trauma. Patients will present complaining of pain near the level of the calcaneocuboid joint. Paresthesias may also be present if there is an injury to the sural nerve. Method of testing consists of having the patient perform a heel-rise test or have the patient invert the foot; both will elicit pain (4).

DIAGNOSTIC TOOLS

Many experts warn against relying too much on the results of the imaging studies, especially with the results from MRIs, because of the number of false-positive and false-negative findings.

Crim (26) admitted imaging modalities should not play a large role in diagnosing peroneal disorders. A thorough history and physical exam is more reliable in developing a definitive diagnosis and treatment plan (4,9,13).

RADIOGRAPHS

X-rays should be taken on any patient complaining of lateral ankle pain. Radiographs are good for evaluating various acute and chronic bone injuries and are important in the patient's initial assessment. The standard AP, lateral, and mortise views of the foot and ankle should be taken, preferably weight-bearing. An axial view may further aid in analyzing the fibular groove, the peroneal tubercle and for a varus deformity (Fig. 77.9). In acute settings, an increase in the volume of the soft tissue can be seen over the lateral ankle. It has been estimated that the os peroneum is ossified in 20% of the population. If present, bilateral views should be taken. In the cases of a suspected os peroneum fracture or separation of a multipartite os peroneum, serial radiographs need to be taken to show the presence of the formation of bone callus or migration of the fragments. When comparing the x-rays of both feet, a proximally displaced or fragmented os peroneum is indicative of a tear in the peroneus longus tendon. A rare finding is the fleck sign. This is an avulsion off the posterolateral aspect of the fibula and is pathognomonic for a grade III rupture of the superior peroneal retinaculum (4,5,10,12,13,19–21).

COMPUTED TOMOGRAPHY

Computed tomography scanning is excellent for evaluating bony pathology that can occur concomitantly with peroneal tendon disorders, that is, calcaneal fractures. In cases of peroneal subluxation, CT scans are a valuable tool in defining the contour of the fibular groove. The biggest limitation of CT scans is the poor tissue resolution, making an MRI the more superior choice when examining intrinsic tendon disorders (4,5,10,21,26).

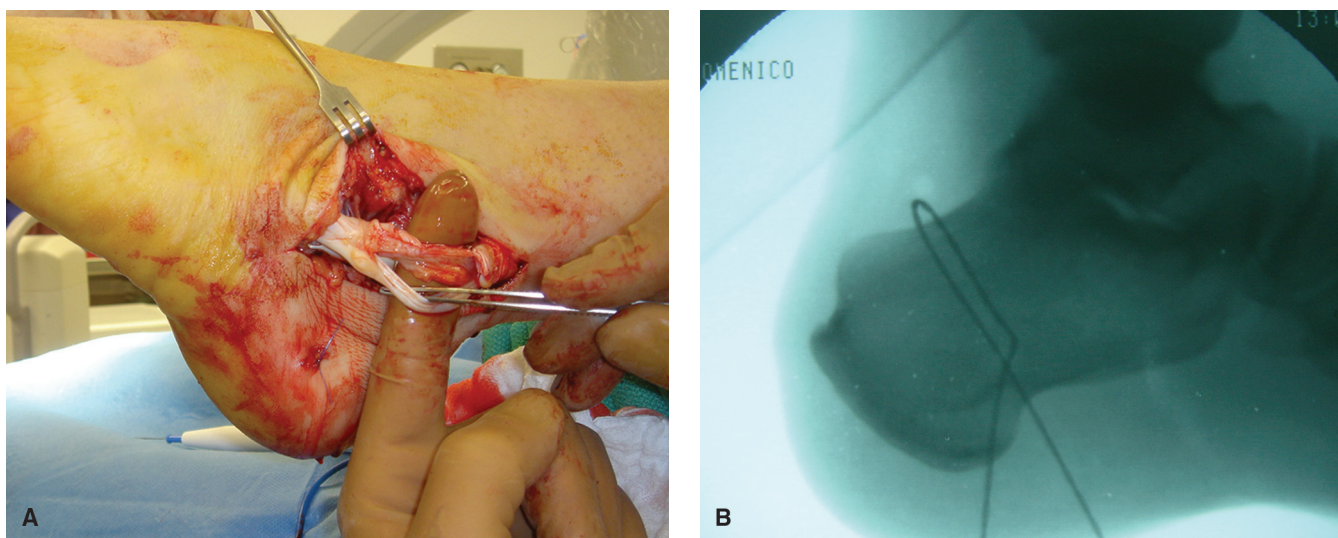


Figure 77.9 **A:** A virtual complete rupture of the peroneus brevis tendon in the retro- and inframalleolar margin. This patient has a history of a chronic ankle sprains associated with a calcaneal varus deformity. **B:** Intraoperative view prior to performing a percutaneous calcaneal displacement osteotomy to move the calcaneus out of a varus deformity into a neutral position. (Continues on next page)

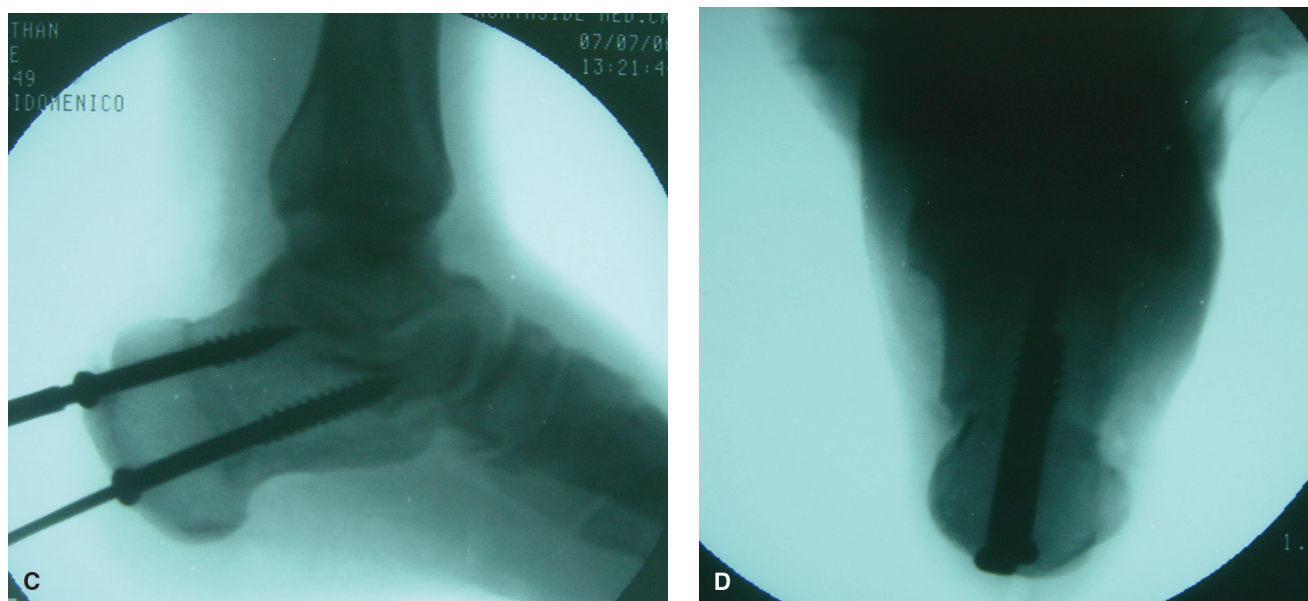


Figure 77.9 (Continued) **C:** An intraoperative lateral fluoroscopy demonstrating internal fixation following the calcaneal displacement osteotomy from a varus position into a neutral position. **D:** An intraoperative calcaneal axial view demonstrating the calcaneus in a more neutral position.

ULTRASOUND

There are three advantages to ultrasound: its low cost, no radiation exposure, and it is noninvasive. This modality is more reliable in picking up disorders with the peroneal tendons than an MRI. Ultrasound can give real-time imaging, which makes this an ideal tool for viewing tendon subluxation and split tears with an accuracy rate reported to be 90% to 100%. Its downfall is the fact that this modality relies heavily on the skills of the operator (4,5,12).

PERONEAL TENOGRAPHY

Tenography has limited use and has essentially been replaced by MRIs (4,5).

MAGNETIC RESONANCE IMAGING

Magnetic resonance imaging is considered to be the gold standard for evaluating disorders of the peroneal tendons (4,5,19–21). However, some experts feel MRIs should be performed only on those patients who have failed conservative treatment and those patients who have symptoms of chronic lateral ankle pain (20). When interpreting MRI findings, it is important to be aware of the chance of false-positive and false-negative results. For example, a false-negative interpretation can occur in cases of peroneal subluxation. Movement of the tendons out of the fibular groove occurs under stress. When undergoing an MRI, the ankle is in a relaxed position. The relaxed state allows the peroneal tendons to relocate into their proper position (10,23). A false-positive interpretation can be secondary to the magic angle phenomenon. This effect occurs any time a tendon is oriented 55 degrees to the external magnetic field. This gives off a signal on T1-weighted images, while there is a disappearance of the signal on T2-weighted images.

This signal artifact gives the false notion of the presence of a tendon tear. The magic angle is most prevalent in the ankle as the medial and lateral tendons curve around the malleoli. A true peroneal tendon tear will show signs of inflammation within the tendon sheath and the surrounding adipose tissue as well as an increased tendon width. A magic angle effect will show the signal artifact in the absence of inflammation. The width of the tendon will also be normal. Another distinction is the presence of the abnormal tendon signal on one or more images. A magic angle signal will only be displayed on T1-weighted images, while an actual tendon tear will display signal abnormalities on both T1- and T2-weighted images. Therefore, abnormalities are accurately diagnosed when a signal is present on more than one image. To avoid this phenomenon, experts recommend imaging the ankle in plantarflexion (26–28).

To further complicate the issue, findings considered to be abnormal when visualized on an MRI can also be present in people who are asymptomatic. A study performed by Saupe et al (8) showed that many of the anatomical variants that predispose a person to peroneal disorders also are commonly found in asymptomatic individuals. With the findings of their study, they developed guidelines to aid in determining if an anatomical variant will become problematic:

- Enlarged peroneal tubercle. A peroneal tubercle is considered hypertrophied if it is greater than 5 mm high.
- Low-lying muscle belly. A peroneus brevis muscle belly extending more than 15 mm beyond the tip of the lateral malleolus may predispose someone to peroneal tendon disorders.
- Shape of the fibular groove. In their study, they found 72% of the asymptomatic volunteers had a convex, flat, or an irregularly shaped fibular groove. If an individual has to undergo surgery for peroneal dislocation, then a groove-deepening procedure is recommended (4,8,28).

There is a wide overlap between MRI findings in patients with peroneal tendinopathy and tenosynovitis, and those with no clinical evidence of peroneal disorders. Therefore, Kijowski et al established a set of criteria for MRI findings to differentiate what is pathologic and what can be a normal finding. For tendinopathy, uniform, intermediate signal intensity must be present within the peroneal tendons on three consecutive axial images. Tenosynovitis must show circumferential fluid within the tendon sheath measuring 3 mm or more at its maximal width (28).

SURGICAL TREATMENT

When surgical repair is performed on an acute peroneal injury, the outcome is favorable; however, when repair is performed on a chronic injury or if the problem involves both the brevis and longus tendons, the success of the surgical outcome is less favorable (29). Siegel et al cautioned against performing a surgical correction on adolescents with peroneal disorders. He admits that although this will make the management and treatment aspects more difficult, waiting until the bone matures will give a better surgical outcome (30).

Regardless of the type of peroneal tendon disorder, it is imperative that any and all associated pathologic variants and concomitant injuries be addressed in the repair process. This will greatly increase the rate of long-term success.

TENDINITIS AND TENOSYNOVITIS

Prolonged activity or activity that is repetitive is the primary cause of inflammation of the tendon or the tendon sheath. Other causes can be due to direct trauma, severe ankle sprains, chronic ankle instability, and hindfoot fractures (4). Specifically, hypertrophy of the peroneal tubercle can be a source of mechanical trauma to the peroneus longus tendon. The hypertrophic tubercle causes a sharp change in the course of the peroneus longus because it pushes the tendon inferiorly. This sharp turn leads to inflammation (11). In certain cases, the tubercle can be enlarged to the point in which it actually

forms a bony tunnel surrounding the peroneus longus tendon. This over time will lead to impingement and stenosing of the tendon (6). Taki et al described a case of bilateral hypertrophic peroneal tubercle on an 11-year-old boy. After successful excision of the enlarged tubercles, histologic findings pointed to bilateral osteochondromas (11).

Tendinitis and tenosynovitis are usually treated conservatively; however, if conservative treatment fails, surgical correction is warranted (5). The surgical technique consists of making an incision in line with the course of the peroneal tendons beginning 1 cm proximal to the tip of the lateral malleolus and ending just 1 cm proximal to the base of the fifth metatarsal. As with any lateral incision, care is taken to retract the sural nerve out of the surgical field. Once dissection is taken down and the tendon sheath is exposed, a similar longitudinal incision is made to expose the peroneal tendons. All inflammatory tissue is débrided away and any abnormality that is present needs to be corrected at this time. This consists of excision of any portion of tendon that is degenerated, excision of a peroneus quartus muscle or low-lying peroneus brevis muscle belly, and excision of a hypertrophic peroneal tubercle. When an enlarged tubercle is excised, bone wax needs to be applied to the exposed cancellous bone to prevent its adherence to the tendons (13). If the additional abnormalities are not addressed, the surgical outcome will be unsuccessful secondary to continued pain and inflammation (4).

TEARS AND RUPTURES

Longitudinal split tears of the peroneus brevis tendon occur consistently on its anterior surface where it bends around the retromalleolar groove (Fig. 77.10) (20). The tears can be found in conjunction with various disorders and pathologies of the lateral ankle such as ankle sprains, peroneal subluxation, and chronic tendinitis. An ankle sprain, whether acute or chronic, causes the peroneus longus tendon to impinge onto the brevis tendon in the posterior aspect of the fibula (4,5,13,20). This repeated friction causes inflammation and degeneration resulting in a split tear. Injury to the superior peroneal retinaculum allows the peroneus brevis tendon to sublux and glide

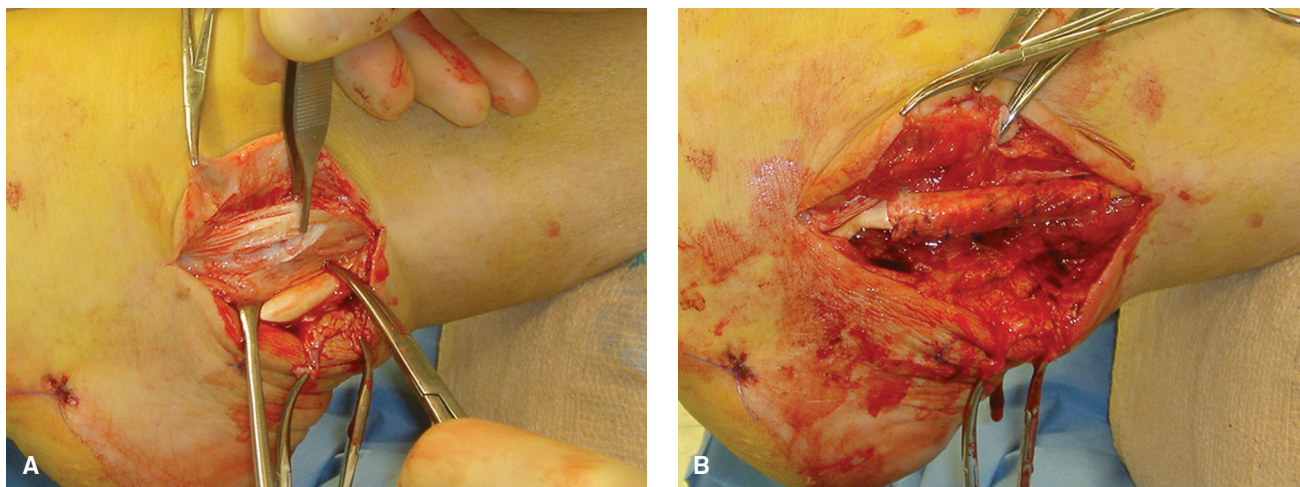


Figure 77.10 **A:** Intraoperative view of a peroneus brevis longitudinal tear. **B:** Intraoperative view following application of an allograft to the peroneus brevis tendon for tendon augmentation.

over the sharp edge of the posterolateral fibula, eventually causing a split tear (2,5,12,13,20). Tears can also result from stenosing of the peroneus brevis tendon in the retromalleolar groove. The stenosis results from increased pressure placed on the brevis tendon from a peroneus quartus muscle or a low-lying peroneus brevis muscle belly. Stenosis can also be caused by the progression of undiagnosed or untreated tenosynovitis (4). Finally, anytime there is an injury to the base of the fifth metatarsal, a rupture of the peroneus brevis at this level must be ruled out (4,13).

Tears in the peroneus longus tendon are usually due to sports injuries but have also been linked to trauma, lateral ankle instability, and subluxation of the peroneal tendons (4,5). Brandes et al described three areas or zones along the peroneus longus tendon where most injuries occur. These zones correspond to the three locations where the tendon changes direction: (a) at the level of the lateral malleolus, (b) as it runs under the peroneal tubercle, and (c) as it makes the sharp medial turn at the cuboid groove (31). A fourth area can be added to include injuries at the os peroneum, if present (4,5). Brandes also noted those patients with an acute onset of pain tended to suffer a rupture at the cuboid groove, whereas those patients that described a more chronic development of symptoms were more likely to have a partial tear or split tear of the tendon at the level of the peroneal tubercle (31).

Slater et al emphasized when considering surgical repair, many factors need to be taken into account. These include the age and activity level of the patient, the specific area where the tendon is torn, the extent of the tear itself, the quality of the remaining tissue, both muscle and tendon, and, of course, any associated or causative anatomical factors (12). The type of operative procedure performed depends on the severity of the tendon tear or rupture, which is based on surgical findings (4,13). The basic surgical technique involves an 8- to 10-cm incision made midway between the lateral border of the Achilles tendon and the lateral malleolus following the course of the peroneal tendons. This position of the incision will most likely not involve the sural nerve; however, if the nerve is visualized, especially as the incision progresses distally, it is gently retracted out of the surgical field so as to prevent injury. Dissection is taken down to the level of the superior peroneal retinaculum, which is inspected for any tears or laxity. Moving the ankle through its range of motion will determine if there is any subluxation of the tendons. At this point, an incision is made into the superior peroneal retinaculum leaving a 4-mm lip of retinaculum on the fibula, so repair can be done without choking the tendons (13). The tendons are manipulated and inspected for any injury. When the tear is identified, it is corrected by either tubularization or by excision and tenodesis (20).

Krause and Brodsky developed guidelines for surgically repairing split tears of the peroneus brevis tendon. After excision of the degenerated portion of tendon, the remaining viable tendon is looked at in cross-section. If 50% or more of the tendon is present, the tendon is tubularized with a running absorbable suture. If less than 50% of the tendon on cross-section is viable, the brevis tendon is tenodesed to the peroneus longus tendon. If a tenodesis needs to be performed, the authors further recommend suturing 3 to 4 cm proximal and 5 to 6 cm distal to the tip of the lateral malleolus so as to prevent impingement against the fibula (32). As a general observation from their study, Krause and Brodsky pointed out if the tear is confined to one aspect of the tendon, the surgical repair has a

better outcome compared with the outcome of repairing multiple tears in the tendon's central aspect (32).

In acute cases of a peroneus brevis tendon rupture, an end-to-end repair is done when there is enough tendon available. If the deficit is too wide, a transfer of the flexor digitorum longus tendon onto the peroneus brevis tendon is performed (5,12). Other tendon graft options include an interposition graft from the gracilis or semitendinosus and a strip from the iliotibial band. In cases in which a cavus deformity along with a plantar-flexed first ray is present, Slater preferred a technique in which the viable peroneus longus tendon is sectioned at the cuboid groove and attached to the base of the fifth metatarsal (12).

The strength of the peroneus longus is twice the strength of the peroneus brevis. When there is a tear of the peroneus longus tendon, net inversion of the foot will result even in the face of an uninjured peroneus brevis (33). Tubularization is preferred if a longitudinal split tear is present within the peroneus longus tendon. Ruptures near the cuboid groove involve excision of the os peroneum if present and performing an end-to-end anastomosis or tubularization. If there is not enough tendon length to do an end-to-end repair, the tendon of the peroneus longus can be anchored into the cuboid or a side-to-side tenodesis with the peroneus brevis can be done. For a side-to-side tenodesis to be successful, the proximal stump of the longus tendon must have enough excursion to prevent the peroneus brevis from locking up (13).

The extent of injury to either tendon cannot be fully appreciated until they are visualized intraoperatively. Redfern and Myerson developed an algorithm to be used as a surgical guide based upon the intraoperative findings. The algorithm takes into account not only the functional state of the peroneal tendons but also the amount of available muscle movement, the amount of stability in the ankle, and the position of the heel (Fig. 77.11) (33). One of three situations can occur: (a) Both peroneal tendons are found to be viable and functional. In this situation, the tendon or tendons are repaired by tubularization. (b) A tenodesis at the musculotendinous junction is performed when one of the tendons is found to be torn and nonfunctional. In order for the tenodesis to be successful, the muscles of both tendons must be free of any scarring and fibrosis. This can decrease the amount of excursion. (c) Lastly, both tendons are found to be nonviable and nonfunctional. When this is the case, the next step is to evaluate the amount of excursion of the peroneal muscles. If excursion is absent, a tendon transfer is performed (33). The flexor digitorum longus' work percentage as well as its extent of muscle excursion is very similar to the peroneus brevis, which makes it the tendon of choice for a transfer procedure (4,5). In most cases, the flexor digitorum longus is transferred to the peroneus brevis; however, transfer of the flexor hallucis longus to the brevis and transfer of the plantaris to the peroneus longus have also been described (33).

In the presence of muscle excursion, the next step is to take note of any scarring of the tissue bed. When there is no scarring, a single-staged tendon graft procedure is performed. The most common type of graft employed is the hamstring allograft (4). For this procedure, the incision and the dissection remain the same and any degenerated tendon is excised. The hamstring allograft is harvested and sutured into the muscle and its proximal tendon. The foot is placed in maximal eversion and the distal aspect of the allograft is either sutured into the remaining peroneus brevis tendon or anchored into the base of the fifth metatarsal (13).

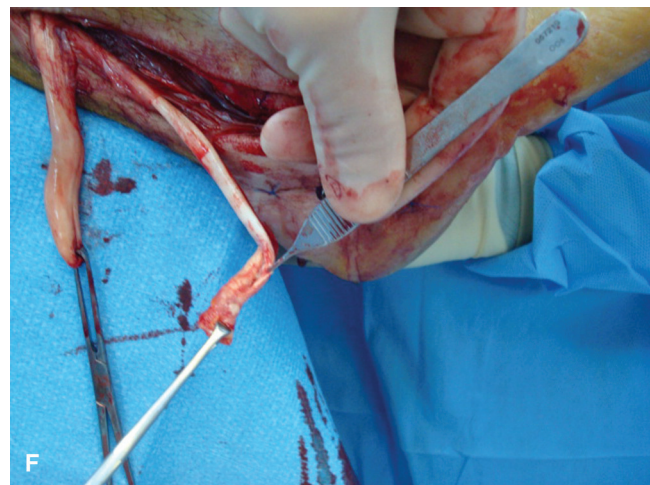
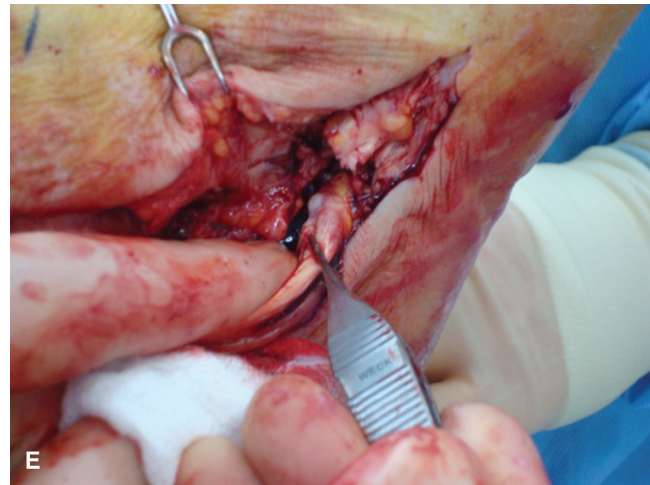
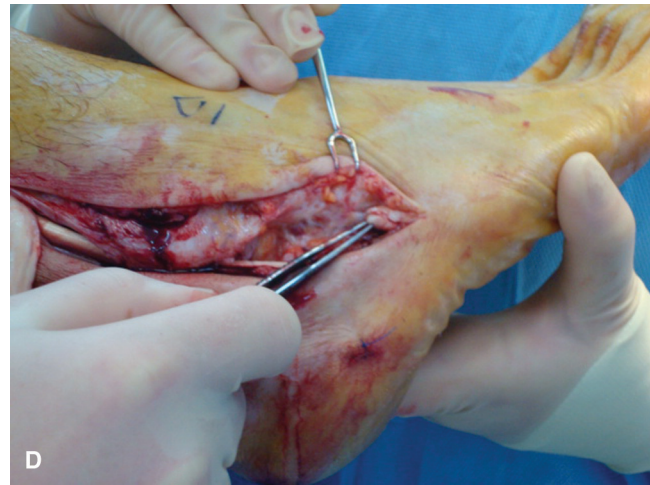
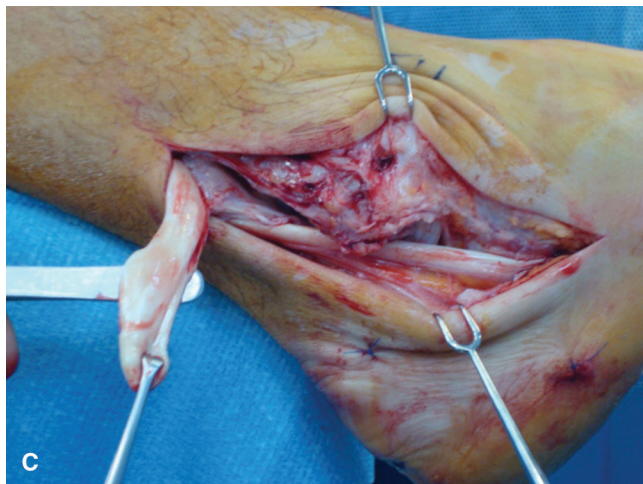
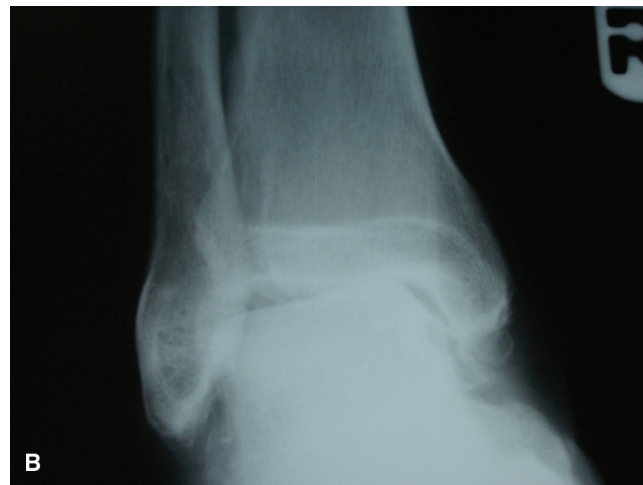
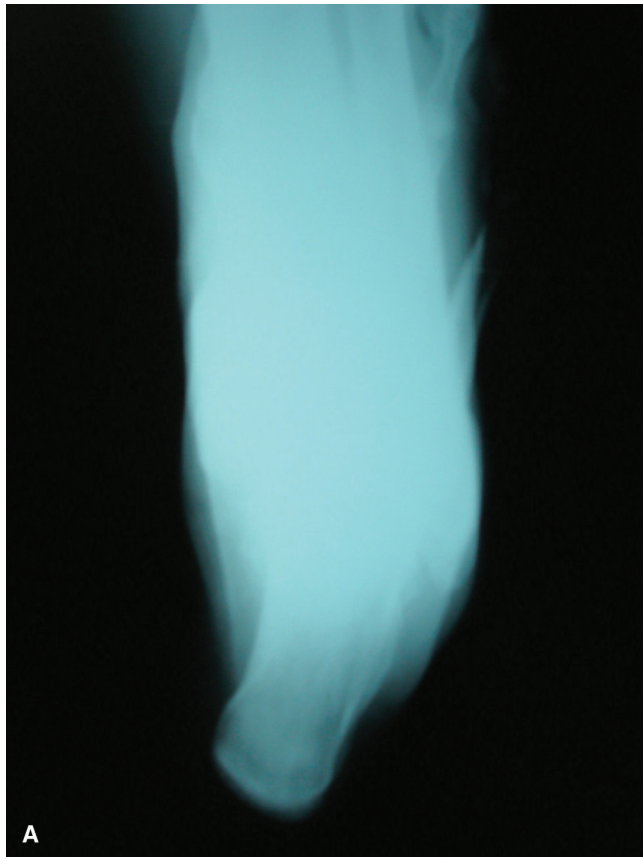


Figure 77.11 **A:** A calcaneal axial-long leg view demonstrating a varus deformity. **B:** A preoperative AP ankle view demonstrating a talar tilt secondary to chronic ankle instability with clinical pain to the lateral ankle. **C:** Intraoperative view demonstrating a chronic long-term tear of the peroneal brevis tendon. Note the sclerotic fibrotic end distal stump. **D:** Intraoperative view demonstrating the distal end of the chronic long-term tear of the peroneal brevis tendon. **E:** Intraoperative view of the peroneal longus tendon demonstrating a diseased area near the cuboid. **F:** Intraoperative view of the peroneal longus tendon demonstrating a longitudinal tear with chronic fibrotic changes. (Continues on next page)

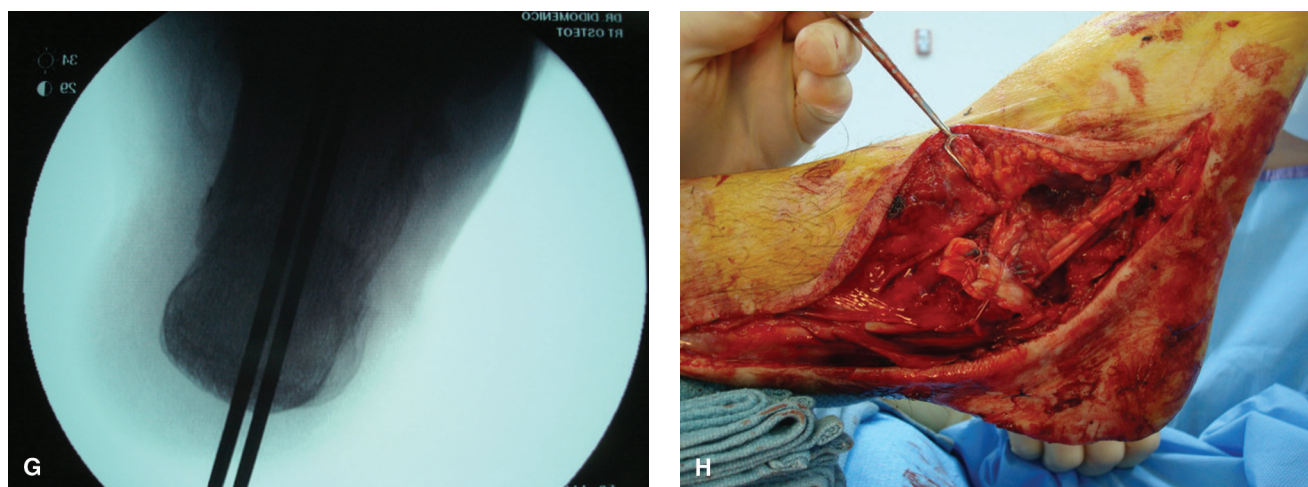


Figure 77.11 (Continued) **G:** Intraoperative calcaneal axial view demonstrating a correction of the preop calcaneal varus deformity. **H:** Intraoperative view following a proximal tenodesis of peroneal brevis into the peroneal longus and the peroneal longus into the stump of the peroneal brevis. The remaining portion of the healthy tendon was used as lateral collateral ligament graft.

A staged tendon graft procedure is utilized if there is any scarring noted in the tissue bed. In his study, Wapner et al described this staged reconstruction procedure in patients with pathology of both peroneal tendons. The first stage of the operation involves excision of any remaining nonviable and degenerated tendon and tendon sheath. A 6-mm silicone Hunter rod is then laid into the bed of the peroneal sheath and sutured onto the stump of the peroneus brevis tendon distally. No suturing or anchoring of the rod is done proximally. At this point, the sheath is brought together and sutured over the rod. Three months later, the second stage is performed, consisting of a flexor hallucis longus tendon transfer. Through a small incision in the proximal aspect of the original incision, the flexor hallucis longus, which was harvested and transferred laterally, is sutured onto the proximal aspect of the Hunter rod. Another small incision is made overlying the area where the rod was sutured onto the brevis stump. The Hunter rod is then released from this distal attachment and is pulled out through the distal incision. This brings the flexor hallucis longus tendon into the newly formed tendon sheath, and the tendon is anchored into the stump of the peroneus brevis tendon (29).

SUBLUXATION AND DISLOCATION

Subluxation or dislocation of the peroneal tendons is frequently overlooked or misdiagnosed as an ankle sprain in acute cases (20). When it is recognized, conservative treatment has a high rate of failure (5). Rosenfeld (19) had determined the failure rate of conservative treatment to be as high as 74%. If the injury is acute, less than 4 weeks old, some feel conservative treatment will work; however, because the success rate is generally less than 56%, this belief is controversial (1). Since the chance of success with conservative treatment is so low, surgical repair of the dislocated peroneal tendons is the treatment of choice. Surgery ensures a satisfactory long-term outcome and should always be considered in chronic cases (1,4).

Most cases of peroneal tendon dislocation are associated with failure of the superior peroneal retinaculum to act as a restraint against the tendons. Eckert and Davis intraoperatively

recognized three patterns of injury to the superior peroneal retinaculum. In their study of 73 patients, not one of them had a tear in the retinaculum itself. Rather, all injuries occurred at the retinaculum's insertion onto the fibular ridge. This is due to the lack of any strong connections of the retinaculum onto the fibrocartilage lip. The three grades of injury are as follows:

1. The superior peroneal retinaculum is elevated from the fibular lip. In this situation, the peroneal tendons were often found over the lateral malleolus and after reduction were unstable only when tension was applied.
2. The superior peroneal retinaculum and a portion of the fibrocartilaginous rim. The tendons are commonly found running over the lateral malleolus but were still very unstable even after reduction.
3. The superior peroneal retinaculum and a cortical fragment from the fibula. The peroneal tendons were consistently found lying over the lateral malleolus and were noted to be very unstable when reduced. This grade is the only injury to the retinaculum that can be identified prior to surgery because the avulsion fracture can be seen on radiograph (34).

In his study, Oden proposed a fourth pattern of injury. This is a rare occurrence in which the superior peroneal retinaculum is elevated off its posterior insertion on the calcaneus. This situation makes reduction of the peroneal tendons impossible because the retinacular flap frequently gets wedged in between the fibular groove and the peroneal tendons (35).

When considering treatment options, Eckert and Davis suggested conservative treatment can be used in grade I and grade III injuries; however, they warn that it is impossible to clinically diagnose what injury was sustained by the superior peroneal retinaculum except for grade III. This fleck or avulsion fracture is such a rare finding that surgical correction is warranted in every case of peroneal dislocation (34).

The techniques used to surgically correct peroneal tendon dislocation fall into one of five categories: primary repair of the superior peroneal retinaculum, tissue transfers, groove-deepening procedures, bone-blocking techniques, and tendon rerouting (20).

Primary reconstruction of the superior peroneal retinaculum.

According to Oden, the goal of reattaching the superior peroneal retinaculum is to restore its restraining function (35). The incision is made along the course of the peroneal tendons and dissection is taken down to the level of the retinaculum. Upon visualization, the retinaculum is lifted off of the posterolateral edge of the fibula, leaving a 5-cm flap still attached (4). A burr or an osteotome is then used to create a trough that is oriented parallel to the remaining edge of the retinacular flap. Three to four drill holes are placed along the trough, and the superior peroneal retinaculum is sutured into the drill holes. The two flaps of retinaculum are then sutured together (4,5). If any attenuation of the retinaculum is present, the excess tissue is excised prior to closure.

Das De and Balasubramaniam (36) noticed that a false pouch, similar to the Bankart lesion in chronic shoulder dislocations, can develop in grade III superior peroneal retinacular injuries. The peroneal tendons were found to easily fall into this pouch with recurrent dislocations. Their technique, coined the Singapore operation, also involved the use of four drill holes and a bony flap (36).

Adachi et al came up with a technique to determine the optimal tension that needs to be placed on the superior peroneal retinaculum when performing a superior retinaculoplasty. They felt it is important to know the proper pullout strength to decrease the risk of overtightening, causing limited joint motion, and insufficient tightening, leading to continued dislocation of the peroneal tendons (37). A Nelaton catheter, 4.7 mm in diameter, was placed alongside the peroneal tendons while the retinaculum was loosely sutured. The catheter was then pulled proximally while keeping the ankle in a neutral position. The authors found the pullout strength to be between 300 and 500 g and thus sutured the retinaculum at this level (37).

TISSUE TRANSFERS

The purpose of performing tissue transfers is to reinforce or recreate the superior peroneal retinaculum (4). A common method used to recreate the retinaculum involves taking a strip of tendon from the lateral aspect of the Achilles, leaving its attachment onto the calcaneus intact and anchoring it into the fibula. While the Achilles tendon graft is being anchored in place, the foot is kept in dorsiflexion so as to prevent against overtightening (4).

In chronic cases of peroneal dislocation associated with ankle instability, Yu and Shook described their preferred technique of recreating the calcaneofibular ligament. Half of the peroneus brevis or longus tendon is harvested and passed in an anterior to posterior direction through a drill hole in the fibula. The harvested tendon is then brought over the peroneal tendons and anchored onto the lateral wall of the calcaneus. The function of the superior peroneal retinaculum is recreated by passing the tendon graft over the peroneal tendons, thus holding them in place (20).

A strip of periosteum can be elevated from the posterior aspect of the fibula near the retromalleolar groove and used to reinforce the superior peroneal retinaculum. This procedure is termed a superior peroneal retinaculoplasty (4). Other tissue grafts can be used; however, Selmani and Armagon advised against their use. They felt the risk of violating the actual

function of these structures is too great (1,5). These tissue grafts include the plantaris tendon, the peroneal brevis tendon, and the gracilis.

GROOVE-DEEPENING PROCEDURES

The goal of deepening the peroneal groove is to prevent subluxation of the tendons while keeping the integrity of the gliding surface intact. Deepening the groove should always be considered in cases in which the groove is anything but concave. This procedure can be used in conjunction with other procedures to maximize long-term success. Complications of the classic groove-deepening procedures are destruction of the fibrocartilaginous gliding surface and the development of a pseudarthrosis (23).

In 1979, Zoellner and Clancy introduced a groove-deepening technique in which a periosteal flap was made encompassing the fibular groove. Their technique eliminated the use of fixation, thus decreasing the risk of complications. In this technique, an osteotome was used to make a bony flap measuring approximately 3 cm in length and 1 cm in width. With the hinge oriented medially, the periosteal flap was swung medially and the subchondral cancellous bone was excised. The flap was then swung back into place and gently depressed 3 to 4 cm into the new trough. After repositioning the tendons, the superior peroneal retinaculum was sutured back into place. If there was any attenuation to the retinaculum, a second periosteal flap from the lateral malleolus was made with the hinge oriented posteriorly. The second bony flap was swung on its hinge and sutured onto the retinaculum (38).

Akiki et al employed a modified version of Zoellner and Clancy's technique. An incision is made along the course of the peroneal tendons, and dissection is taken down to the level of the peroneal retinaculum and tendon sheath. Care is taken to retract the sural nerve if present within the surgical field. A similar longitudinal linear incision, oriented close to the posterolateral rim of the fibula, is made within the sheath and retinaculum to expose the periosteum. The incision into the fibular periosteum must be oriented close to the lip of the lateral fibula to prevent any exposure of the tendons to cancellous bone. A flap of periosteum is then made with the hinge oriented medially, and a burr is used to make a trough in the cancellous bone. Once a sufficient amount of bone is removed, the bony flap is reduced and gently impacted in place. This should deepen the groove by 3 to 8 mm. The peroneal tendons are placed back into their proper position within the groove, and the retinaculum and the tendon sheath are advanced and sutured under the lateral wall of the retromalleolar groove. When redundancy of the retinaculum is present, instead of making a second bony flap, the extra tissue is sewn over utilizing a pants-over-vest suture technique (21).

Ogawa et al described a technique in which the retromalleolar groove was deepened indirectly. Their method does not produce a bony flap (39). The skin incision and dissection remain the same. However, when making the incision into the retinaculum, Ogawa recommended leaving a 3-mm flap of tissue on the fibula. At this point, a large drill is placed at the distal tip of the fibular malleolus just anterior to the groove's surface. The subchondral bone in the posterior ½ of the fibula is reamed using the drill. Care is taken not to damage the groove's fibrocartilaginous surface. A bone tamp is used to gently push the

gliding surface of the groove into the new trough. The peroneal tendons are placed into the groove, and the retinaculum is reapproximated to the 3 mm of tissue flap under mild tension (39).

Walther et al also performed an indirect groove-deepening procedure; however, after the subchondral drilling, a small osteotome was used to perforate the medial and lateral edges of the groove. The gliding surface of the groove was impacted at least 5 mm using a wide bone tamp. The superior peroneal retinaculum was attached to the cancellous bone, which has been exposed because of the groove impaction. The deep soft tissue and skin is reapproximated and sutured accordingly. The purpose of this modification is to protect the retromalleolar groove, which tends to be damaged in other groove-deepening procedures (23).

BONE BLOCKING

Bone blocking employs the use of a fibular osteotomy displaced posteriorly over the peroneal tendons to prevent subluxation (Fig. 77.12) (4). This type of procedure exaggerates the lateral wall of the fibula, providing a bone block, or a bony restraint, against the subluxing tendons. Utilizing a bone-blocking technique increases the risk of nonunion/malunion, tendon irritation from the hardware fixation, and adherence of the tendons to the exposed cancellous bone (1,4).

TENDON REROUTING

These types of procedures reroute the peroneal tendons under the calcaneofibular ligament. Doing this recruits the calcaneofibular ligament into acting as the restraining force against the subluxing peroneal tendons (4,9,20). In essence, the calcaneofibular ligament is recruited to take the place of the incompetent superior peroneal retinaculum (10). The rerouting can

occur in one of two ways, the first procedure involves dividing the tendons, bringing them under the calcaneofibular ligament and then reapproximating then tendon ends. The second procedure involves detachment of the calcaneofibular ligament at either its calcaneal or its fibular insertion and bringing it over the tendons. Wherever the detachment occurs, the ligament remains attached to a bone block, which is used to preserve the calcaneofibular ligament's integrity (20).

INTRASHEATH SUBLUXATION

Also known as pseudosubluxation, intrasheath subluxation was first identified by Raikin et al when they noticed a subgroup of patients with peroneal subluxation in the presence of an intact superior peroneal retinaculum (24,40). The diagnosis is usually difficult and delayed because the physical exam is nonspecific and the workup usually results in negative findings. Symptoms are unresponsive to continued conservative treatment. In these cases, it is very important to examine the contralateral or unaffected ankle (1). Patients in this subgroup present with retromalleolar pain and palpable clicking of the peroneal tendons with ankle circumduction, but dislocation of the peroneal tendons out of the retromalleolar groove is absent. The subluxation is ultimately picked up by means of a dynamic ultrasound (24).

Intrasheath subluxation occurs as one of two types. Type A involves a switching of the brevis and longus tendon positions, that is, the longus is found lying deep to the brevis. No tearing of either tendon is present in this case. A Type B subluxation occurs when the peroneus longus tendon subluxes through a split tear within the brevis tendon, known as a button-hole tear (24). Both types of subluxation occur within the boundaries of the retromalleolar groove and the tendon sheath.

As in cases of peroneal subluxation with a torn superior peroneal retinaculum, intrasheath subluxation does not respond

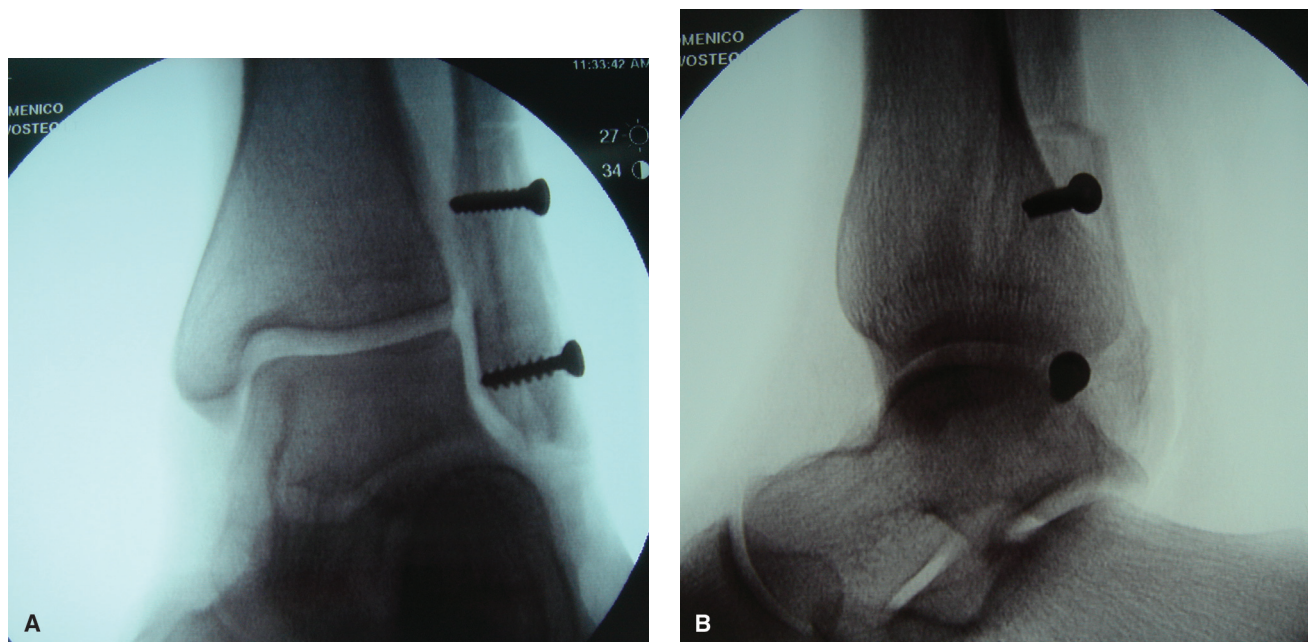


Figure 77.12 Intraoperative AP and lateral ankle views following a fibular osteotomy for a dislocating peroneal tendon pathology.

to conservative treatment; thus, surgical correction is warranted (24,40). The technique used to correct intrasheath subluxation is the same technique used in cases of true peroneal subluxation. After dissection is taken down to the level of the superior peroneal retinaculum, the retinaculum is incised, leaving a 1-mm flap on the fibula. Using an osteotome, the retinacular flap along with the attached periosteum is lifted off the fibula with its hinge oriented posteriorly. Deepening of the groove takes place with the use of a burr, and the periosteal flap is then replaced and impacted in to the trough. At this point, three to four drill holes are placed proximal to distal along the groove's anterior edge. The peroneal tendons are placed back into their proper position within the retromalleolar groove. A 2-0 non-absorbable suture is used to reattach the superior peroneal retinaculum to the undersurface of the groove's anterior edge through the drill holes. The excess retinaculum along with the corresponding periosteum is posteriorly advanced to the posterior portion of the peroneal retinaculum and sutured in place using a pants-over-vest technique. By doubling up the reattachment, this reinforces the retinaculum (24,40). Deep soft tissue and skin is then reapproximated using standard technique.

PAINFUL OS PERONEUM SYNDROME

The primary cause of peroneus longus tendon disorders is the os peroneum. This syndrome includes a number of clinical conditions related to peroneal longus tendon injuries:

- An acute fracture of the os peroneum or a separation of a multipartite bone will lead to discontinuity of the tendon.
- The presence of bone callus secondary to a chronic fracture or separation of a multipartite os peroneum will lead to stenosis of the peroneus longus tendon.
- A partial or complete rupture of the peroneus longus tendon in proximity to the os peroneum. Most ruptures of the longus tendon will occur just distal to the os peroneum. This can be viewed on radiograph in which the os peroneum is positioned in a more proximal position (12).
- The presence of a hypertrophic peroneal tubercle can lead to entrapment of both the peroneus longus tendon and the os peroneum (4).

Surgical correction of this syndrome involves removal of the os peroneum and the hypertrophic peroneal tubercle, if present. Correction also involves the repair of any tearing of the peroneal longus tendon (4).

TENOSCOPY OF THE PERONEAL TENDONS

Endoscopy of the hindfoot and the peroneal tendons, in particular, is a recent development, although still not commonly performed today (14,41,42). The indications for performing a tenoscopy are the same indications when performing an open procedure. However, a tenoscopy of the peroneal tendons offers a number of advantages over an open procedure such as decreased morbidity, a decrease in the level of postoperative pain, being less invasive, an increase in patient satisfaction, better cosmetic result secondary to smaller scars, and a quicker return to activity and work. From the surgeon's perspective, additional advantages include the ability to dynamically test the tendons, the fact that scoping the tendons is more sensitive in detecting any concomitant pathology than ultrasound and MRI, and this procedure can be converted into an open procedure if the need arises (14,41,42).

The surgical technique consists of making an incision for the distal portal 3 to 5 cm distal to the posterior aspect of the lateral malleolus overlying the peroneal tendons. A blunt trocar is inserted into the tendon sheath, followed by a 2.7-mm 30-degree arthroscope. At this point, a spinal needle is inserted 3 to 5 cm proximal to the posterior aspect of the lateral malleolus overlying the peroneal tendons for the proximal portal. Using these two portals, the entire peroneal compartment can be examined and the presence or absence of various pathologies can be determined. Abnormalities such as a low-lying peroneal brevis muscle belly, a shallow groove, adhesions, synovitis, a hypertrophic peroneal tubercle, and tendon tears can be corrected endoscopically. However, Scholten and van Dijk recommend using a third portal placed either proximal or distal to the original two portals if performing a synovectomy (14,41).

POSTOPERATIVE COURSE

The postoperative course is highly dependent on the degree of tendon involvement, the type of surgical correction performed, and the age and activity level of the patient. In general, the postoperative course for the various peroneal tendon surgeries consists of 2 weeks non-weight-bearing in a Jobst compression dressing. After 2 weeks, the sutures are removed and the patient is placed in a non-weight-bearing below-the-knee cast for an additional 2 weeks. Upon removal of the cast, the patient is fitted with orthotic devices, preferably custom-made devices, and started in aggressive physical therapy for 8 to 12 weeks.

SUMMARY

Pathology of the peroneal tendons is an infrequent cause of lateral ankle pain. When pathology of the peroneal tendons is present, it is commonly overlooked and misdiagnosed; therefore, a high index of suspicion is needed to guarantee a better long-term result. Anyone who presents with pain to the lateral aspect of the ankle, calcaneus, and/or the foot should undergo a thorough examination of the peroneal tendons. This thorough history and physical examination is more reliable than diagnostic modalities. Further, the diagnostic modalities, including radiographs, CT scans, ultrasound, and MRI should be used to confirm not diagnose the pathology.

Peroneal tendons disorders can be divided into 4 categories: tendinitis and tenosynovitis, tendon tears and ruptures, subluxation and dislocation, and POPS. Surgical correction is usually warranted secondary to the high rate of failure with conservative treatment. The type of surgery needed depends on the type of disorder present, and they are divided into five categories: primary repair of the superior peroneal retinaculum, tissue transfers, groove-deepening procedures, bone blocking, and tendon rerouting.

REFERENCES

1. Armagon O, Shereff M. Tendon injury and repair. In: Myerson M, ed. *Foot and ankle disorders*. Philadelphia, PA: WB Saunders, 2000:942-971.
2. Steel MW, DeOrto JK. Peroneal tendon tears: return to sports after operative treatment. *Foot Ankle* 2007;28:49-54.
3. Hutchinson B. Repair of peroneal subluxation. In: Chang TJ, ed. *Master techniques in podiatric surgery: the foot and ankle*. Philadelphia, PA: Lippincott Williams & Wilkins, 2005:491-498.
4. Heckman DS, Reddy S, Pedowitz D, et al. Current concepts review: operative treatment for peroneal tendon disorders. *J Bone Joint Surg Am* 2008;90:404-418.

5. Selmani E, Gjata V, Gjika E. Current concepts review: peroneal tendon disorders. *Foot Ankle* 2006;27:221–228.
6. Hyer CF, Dawson JM, Philbin TM, et al. The peroneal tubercle: description, classification, and relevance to peroneus longus tendon pathology. *Foot Ankle* 2005;26:947–950.
7. Petersen W, Bobka T, Stein V, et al. Blood supply of the peroneal tendons. Injection and immunohistochemical studies of cadaver tendons. *Acta Orthop Scand* 2000;71:168–174.
8. Saupe N, Mengiardi B, Pfirrmann CW, et al. Anatomic variants associated with peroneal tendon disorders: MR imaging findings in volunteers with asymptomatic ankles. *Radiology* 2007;242:509–517.
9. Ferran NA, Maffulli N, Oliva F. Management of recurrent subluxation of the peroneal tendons. *Foot Ankle Clin North Am* 2006;11:465–474.
10. Ogawa BK, Thordarson DB. Current concepts review: peroneal tendon subluxation and dislocation. *Foot Ankle* 2007;28:1034–1040.
11. Taki K, Yamazaki S, Majima T, et al. Bilateral stenosing tenosynovitis of the peroneus longus tendon associated with hypertrophied peroneal tubercle in a junior soccer player: a case report. *Foot Ankle* 2007;28:129–132.
12. Slater HK. Acute peroneal tendon tears. *Foot Ankle Clin N Am* 2007;12:659–674.
13. Squires N, Myerson MS, Gamba C. Surgical treatment of peroneal tendon tears. *Foot Ankle Clin North Am* 2007;12:675–695.
14. van Dijk CN. Hindfoot endoscopy for posterior ankle pain. *Instr Course Lect* 2006;55:545–554.
15. DiGiovanni BF, Fraga CJ, Cohen BE, et al. Associated injuries found in chronic lateral instability. *Foot Ankle* 2000;21:809–815.
16. Root ML, Orien WP, Weed JH, eds. *Clinical biomechanics II. Normal and abnormal function of the foot*. Los Angeles, CA: Clinical Biomechanics, 1977.
17. Lagoutaris ED, Adams HB, DiDomenico LA, et al. Longitudinal tears of both peroneal tendons associated with tophaceous gouty infiltration. A case report. *J Foot Ankle Surg* 2005;44:222–224.
18. Perlman M, Boberg J, Kalish SR, et al. Chronic ankle conditions. In: McGlamery E, ed. *Comprehensive textbook of foot surgery*. 2nd ed. Baltimore, MD: Williams & Wilkins, 1992:989–1026.
19. Rosenfeld P. Acute and chronic peroneal tendon dislocations. *Foot Ankle Clin North Am* 2007;12:643–657.
20. Yu GV, Shook JE. Peroneal tendon pathology. In: Scurren B, ed. *Foot and ankle trauma*. 2nd ed. New York: Churchill Livingstone, 1996:715–729.
21. Akiki A, Arlettaz Y, Crevoisier X. Peroneal tendon dislocation: a tendon protective and bone preserving technique of stabilization. *Saudi Med J* 2007;28:1607–1609.
22. Klein SE, Varner KE, Marymont JV. Lateral talar process fracture and peroneal tendon dislocation: a previously unrecognized injury complex. *Foot Ankle* 2008;29:1020–1024.
23. Walther M, Morrison R, Mayer B. Retromalleolar groove impaction for the treatment of unstable peroneal tendons. *Am J Sports Med* 2009;37:191–194.
24. Raikin SM, Elias I, Nazarian LN. Intrasheath subluxation of the peroneal tendons. *J Bone Joint Surg Am* 2008;90:992–999.
25. Safran MR, O'Malley D, Fu FH. Peroneal tendon subluxation in athletes: new exam technique, case reports, and review. *Med Sci Sports Exerc* 1999;31:S487–492.
26. Crim J. *Imaging of the foot and ankle*. London, UK: Lippincott-Raven, 1996.
27. Rolles R, Pomeranz SJ, Kim TW. Tendons. In: Clyde C, ed. *MRI of the foot and ankle. Pearls, pitfalls and pathology*. 1st ed. Cincinnati, OH: MRI EFI Publications, 2002:13–30.
28. Kijowski R, De Smet A, Mukharjee R. Magnetic resonance imaging findings in patients with peroneal tendinopathy and peroneal tenosynovitis. *Skeletal Radiol* 2007;36:105–114.
29. Wapner KL, Taras JS, Lin SS, et al. Staged reconstruction for chronic rupture of both peroneal tendons using hunter rod and flexor hallucis longus tendon transfer: a long-term followup study. *Foot Ankle* 2006;27:591–597.
30. Siegel RM, Schubiner J, Sammarco VJ. A nonoperative treatment technique for peroneal tendon subluxation. *Clin Pediatr* 2008;47:300–301.
31. Brandes CB, Smith RW. Characterization of patients with primary peroneus longus tendinopathy: a review of twenty-two cases. *Foot Ankle* 2000;21:462–468.
32. Krause JO, Brodsky JW. Peroneus brevis tendon tears: pathophysiology, surgical reconstruction, and clinical results. *Foot Ankle* 1998;19:271–279.
33. Redfern D, Myerson M. The management of concomitant tears of the peroneus longus and brevis tendons. *Foot Ankle* 2004;25:695–707.
34. Eckert WR, Davis EA. Acute rupture of the peroneal retinaculum. *J Bone Joint Surg Am* 1976;58:670–673.
35. Oden RR. Tendon injuries about the ankle resulting from skiing. *Clin Orthop Relat Res* 1987;216:63–69.
36. Das De S, Balasubramaniam P. A Repair operation for recurrent dislocation of peroneal tendons. *J Bone Joint Surg* 1985;67-B:585–587.
37. Adachi N, Fukuhara K, Tanaka H, et al. Superior retinaculoplasty for recurrent dislocation of peroneal tendons. *Foot Ankle* 2006;27:1074–1078.
38. Zoellner G, Clancy W. Recurrent dislocation of the peroneal tendon. *J Bone Joint Surg Am* 1979;61-A:292–294.
39. Ogawa BK, Thordarson DB, Zalavras C. Peroneal tendon subluxation repair with an indirect fibular groove deepening technique. *Foot Ankle* 2007;28:1194–1197.
40. Raikin SM. Intrasheath subluxation of the peroneal tendons. surgical technique. *J Bone Joint Surg Am* 2009; 91S:146–155.
41. Scholten PE, van Dijk CN. Tendoscopy of the peroneal tendons. *Foot Ankle Clin North Am* 2006;11:415–420.
42. Jerosch J, Aldawoudy A. Tendoscopic management of peroneal tendon disorders. *Knee Surg Sports Traumatol Arthrosc* 2007;15:806–810.